



Investigation of an appropriate decalcifying agent for bone biopsy specimens submitted for histomorphologic analyses and immunohistochemical studies

Joel S. Morcilla, MSMLS¹, Dr. Issam Al Bozom², Dr. Ammar Adham³, Dr. Khaled Murshed⁴,
& Leah F. Quinto, PhD⁵

¹Mayo Clinic Health System, Anatomic Pathology, Eau Claire, Wisconsin, United States of America,

^{2,3,4}Hamad Medical Corporation, Hamad General Hospital, Histopathology Section, Doha, Qatar,

⁵De La Salle Medical and Health Sciences Institute, Dasmariñas, Cavite, Philippines

Corresponding Author: ¹Morcilla.Joel@mayo.edu, ²Ialbozom@hamad.qa, ³AAmmar1@hamad.qa, ⁴KMurshed@hamad.qa,
⁵lfquinto@dlsmhsi.edu.ph

Abstract

Decalcification is a critical pre-analytical step in histopathology for mineralized tissues, yet inappropriate agent selection and endpoint control can compromise histomorphologic detail and reduce the interpretability of immunohistochemical (IHC) stains. This study compared the effectiveness of five decalcifying agents for bone biopsy specimens intended for routine histomorphologic evaluation and downstream IHC: 10% hydrochloric acid (HCl), 15% formic acid (FA), Gooding and Stewart (formalin–formic acid), ethylenediaminetetraacetic acid (EDTA), and formic acid–EDTA (FEDTA). Ten bone biopsy specimens were decalcified using each agent, and decalcification endpoints were determined via physical and chemical testing. Morphologic preservation was assessed on hematoxylin and eosin (H&E)–stained sections using structured scoring of cellular and extracellular features, while IHC performance was evaluated using CD34, S100, SATB2, and SMA markers, scored for signal intensity/reactivity. The fastest decalcification endpoint was achieved by 10% HCl (mean 6.30 hours), whereas EDTA required the longest processing time (mean 159.20 hours). Despite slower turnaround, EDTA produced the highest overall H&E preservation score (mean 13.25/15), indicating superior retention of key histomorphologic structures. In contrast, 15% FA demonstrated relatively weaker SATB2 reactivity (mean 1.70), suggesting greater vulnerability of specific antigen targets under stronger acid conditions. Across the five agents, no statistically significant differences were detected among IHC marker outcomes (all p-values > 0.05), although EDTA and FEDTA tended to yield higher mean marker scores in several comparisons. Overall, EDTA is recommended when maximal morphologic preservation and future tissue usability (repeat IHC and ancillary testing) are priorities, while acid-based agents may be reserved for situations where rapid turnaround is essential and modest trade-offs in tissue integrity are acceptable.

Keywords: *Decalcification; Bone biopsy; Histomorphology; Immunohistochemistry; Ethylenediaminetetraacetic acid (EDTA); Formic acid; Hydrochloric acid; Gooding and Stewart solution; Decalcification endpoint; Antigen preservation; protocol optimization*

1. Introduction

Decalcification is a routine yet consequential pre-analytical step in the histopathologic evaluation of bone biopsies. Mineralized tissue must be sufficiently decalcified to permit microtomy and produce diagnostically interpretable sections; however, the same chemical processes that remove calcium can also alter tissue morphology, compromise antigenicity, and reduce the integrity of nucleic acids needed for downstream assays (Chappard, 2015; Dey, 2018). As diagnostic practice increasingly relies on immunohistochemistry (IHC) and, in selected contexts, molecular testing, decalcification choice has become more than a technical preference—it functions as a controllable source of analytical variability that can affect result

quality and reproducibility (Bourhis et al., 2019; Hao et al., 2002).

Multiple decalcification approaches are available, but they involve well-described trade-offs between speed and preservation. Strong acids can shorten turnaround time but are more likely to cause swelling, loss of cytologic detail, and degradation of protein epitopes, which may yield diminished or false-negative immunostaining (Choi et al., 2015; Kapila et al., 2015). Even weak acids, while generally gentler than strong acids, may still compromise DNA quality or reduce the success of molecular procedures under certain conditions (Wickham et al., 2000). In contrast, chelating agents such as ethylenediaminetetraacetic acid (EDTA) decalcify by binding calcium ions rather than dissolving mineral via acid hydrolysis; this

mechanism is frequently associated with better preservation of morphology and biomolecules, albeit at the cost of markedly longer decalcification times (Dey, 2018; Liu et al., 2017).

Recent evidence supports the practical importance of these differences. For example, EDTA-based decalcification has been associated with more favorable preservation for ancillary testing, including IHC and selected molecular workflows, compared with acid-based methods (Miquelestorena-Standley et al., 2020; Schrijver et al., 2016). In breast cancer bone metastasis material, EDTA decalcification has been reported to retain reliable interpretation for key predictive biomarkers such as ER, PR, and HER2 (van Es et al., 2019). Hybrid protocols that combine EDTA with weak acids have also been explored as potential compromises intended to reduce processing time while protecting histologic and immunophenotypic interpretability (Eloka et al., 2012; Thorat et al., 2011).

Despite the existing literature, many diagnostic laboratories continue to use conventional acid-based protocols due to operational constraints and the need for timely reporting, and there remains practical uncertainty about which agent offers the most defensible balance between turnaround time and quality outcomes for routine bone biopsy workups. Moreover, comparatively few studies explicitly evaluate multiple decalcifying agents using both (a) structured hematoxylin-and-eosin (H&E) morphology metrics and (b) IHC quality indicators in a standardized comparative framework designed to support evidence-based protocol selection within a specific laboratory context. Accordingly, the present study is positioned as a laboratory validation and protocol-optimization effort that quantitatively compares commonly used decalcifiers and EDTA-based options using clinically relevant quality endpoints for H&E and IHC.

Objectives and Hypotheses

General Objective

To determine the most effective decalcifying agent for bone biopsy specimens, evaluated through (a) decalcification endpoint time and (b) preservation of histomorphologic and immunohistochemical quality as measurable laboratory quality metrics.

Specific Objectives

To determine and compare the decalcification endpoint time of the decalcifying agents using standardized endpoint criteria (physical and chemical), as a workflow/turnaround-time metric.

To describe and compare histomorphologic preservation in hematoxylin and eosin (H&E) stained sections across decalcifying agents, using structured scoring of nuclear membrane, nucleoli, chromatin, cytoplasm, and extracellular matrix.

To describe and compare immunohistochemical staining quality across decalcifying agents using a defined marker panel (CD34, S100, SATB-2, and SMA), using structured scoring of staining reaction characteristics.

To compare decalcifying agents across H&E and IHC quality metrics to identify the decalcifier(s) that best preserve diagnostic utility while remaining operationally feasible.

To identify, based on the combined evidence from endpoint time and quality metrics, the decalcifying agent that is most appropriate for routine bone biopsy processing where histomorphology and IHC performance are critical.

Hypotheses

H1: EDTA-based decalcification will yield higher histomorphologic preservation scores than strong- and weak-acid decalcification approaches.

H2: Overall IHC quality scores will show limited differences across decalcifiers for most markers; however, acid-based agents will demonstrate comparatively greater degradation in at least some IHC staining quality metrics.

2. Review of Related Literature

2.1 Decalcification as a quality-critical pre-analytical process

Decalcification is a standard histotechnology procedure in which calcium salts are removed from mineralized tissues to enable sectioning and microscopic evaluation (Carson & Cappellano, 2016; Dey, 2018). While the operational goal is to soften tissue enough for microtomy, the procedure is inherently quality-critical because decalcification conditions can modify the microscopic features that pathologists rely upon for diagnosis and can influence downstream assay suitability (Miquelestorena-Standley et al., 2020). In practical

laboratory terms, decalcification is therefore not merely preparatory; it is a pre-analytical determinant of diagnostic interpretability, particularly when morphology and immunohistochemical performance must be preserved for clinically meaningful decision-making (Schrijver et al., 2016).

The importance of decalcification quality becomes especially pronounced in bone biopsy and marrow-related specimens, where cellular detail, marrow architecture, and stromal characteristics are integral to interpretation (Chappard, 2015). Because many laboratories also apply immunohistochemistry and, increasingly, molecular assays to such specimens, decalcification must be evaluated not only by whether it achieves endpoint decalcification, but by whether it preserves the tissue and biomolecular features necessary for ancillary diagnostics (Miquelestorena-Standley et al., 2020; Schrijver et al., 2016).

2.2 Major categories of decalcification methods and the speed–preservation trade-off

The literature describes several methodological approaches to decalcification, with particular emphasis on acid-based decalcification and chelation-based decalcification, each associated with predictable advantages and risks (Callis & Sterchi, 2013; Dey, 2018). Acid decalcification is often selected for speed and workflow convenience, especially in routine settings where turnaround time is a major operational constraint (Dey, 2018). However, acid exposure can also increase the risk of morphologic distortion and reduced preservation of proteins and nucleic acids needed for immunohistochemical and molecular testing (Schrijver et al., 2016; Wickham et al., 2000).

Chelation-based decalcification—most commonly associated with EDTA—operates through binding calcium ions rather than dissolving mineral through acid reaction (Dey, 2018). This mechanism is widely framed as more protective of morphology and antigen structures, which is relevant to both routine histology and immunohistochemistry (Miquelestorena-Standley et al., 2020; Milestone, 2020). The trade-off is time: EDTA-based procedures are frequently slower, potentially affecting laboratory throughput and reporting schedules (Dey, 2018; Choi et al., 2015).

In applied laboratory decision-making, the central problem is therefore a balancing act: faster approaches may increase the probability of quality compromise, while more preservation-oriented approaches may increase turnaround time and operational burden (Callis & Sterchi, 2013; Dey, 2018).

2.3 Effects of decalcification on morphology and routine staining quality

Histologic quality is commonly assessed through preservation of nuclear detail, cytoplasmic clarity, stromal definition, and absence of processing artifacts, all of which influence diagnostic confidence (Carson & Capellano, 2016; Brown, 2009). Decalcification may contribute to artifacts such as tissue swelling, loss of cellular crispness, and altered staining behavior, particularly when exposure is prolonged or endpoint monitoring is inconsistent (Dey, 2018; Callis & Sterchi, 2013). The practical implication is that decalcification protocols should not be evaluated solely by completion time, but also by the extent to which they preserve interpretability under routine hematoxylin-and-eosin staining and related histologic workflows (Carson & Capellano, 2016; Chappard, 2015).

Laboratory manuals and methodological studies emphasize that many common problems observed on slides arise from upstream preparation steps rather than from the microscope itself, and decalcification is often highlighted as one of those upstream steps that can systematically shift slide quality across a batch (Brown, 2009; Callis & Sterchi, 2013). As such, protocol selection and monitoring are quality assurance concerns as much as they are technical choices.

2.4 Decalcification and immunohistochemistry: antigen preservation and interpretability

Immunohistochemistry depends on the preservation of antigen epitopes and tissue structure sufficient to support interpretable staining patterns (Gao & Kahn, 2005; Miquelestorena-Standley et al., 2020). Decalcification can influence both: excessive exposure or harsh chemistries may reduce antigen detectability or create background staining patterns that reduce interpretability (Schrijver et al., 2016). Consequently, decalcifier choice becomes consequential in bone-related specimens, where IHC may be required to support lineage identification, tumor classification, and diagnostic clarification (Gao & Kahn, 2005; Chappard, 2015).

Evidence cited in Manuscript A indicates that decalcification procedures can alter IHC performance and that the magnitude of impact can depend on the decalcifier and protocol parameters (Schrijver et al., 2016; Miquelestorena-Standley et al., 2020). Importantly, not all IHC endpoints behave identically: certain markers may remain robust under some protocols, while others may show reduced signal or interpretive ambiguity depending on antigen sensitivity and processing conditions (van Es et al., 2019; Schrijver et al., 2016). This reinforces the need for laboratory-specific validation, particularly when the marker panel used in a facility includes targets that are known to be sensitive to processing variability (Miquelestorena-Standley et al., 2020).

Commercial EDTA-based products are also positioned in the cited literature as supporting immunological and molecular biology procedures by preserving antigen structures through chelation rather than acid dissolution (Milestone, 2020). Although such documentation provides a rationale for EDTA use, it also underscores the requirement for correct preconditions and monitoring, indicating that preservation advantages are contingent on protocol discipline rather than guaranteed by reagent type alone (Milestone, 2020).

2.5 Decalcification and molecular diagnostics: preservation of nucleic acids and analytic reliability

Beyond IHC, the literature cited in Manuscript A emphasizes molecular implications of decalcification, particularly the preservation of DNA for amplification, sequencing, and mutation analysis (Wickham et al., 2000; Bourhis et al., 2019). Acid decalcification has been reported to degrade DNA in certain specimen contexts, potentially limiting amplification of longer PCR products and thereby constraining molecular diagnostics (Wickham et al., 2000). Correspondingly, EDTA is repeatedly positioned as a preferable decalcifier when the downstream intent includes assays reliant on nucleic acid integrity (Alers et al., 1999; Wickham et al., 2000).

At a practical level, the cited literature also documents that decalcification may lead to failure of specific molecular tests and mutation-associated immunohistochemical procedures under some conditions, signaling that decalcification can function as a hidden source of false negatives or non-informative results if protocols are not aligned to diagnostic goals (Bourhis et al., 2019). Even where a laboratory's primary endpoint is histomorphology, these molecular findings matter because modern diagnostic workflows increasingly integrate IHC and molecular assays as adjuncts to morphology, especially in oncologic contexts (Miquelestorena-Standley et al., 2020; Schrijver et al., 2016).

2.6 Endpoint monitoring and process control in decalcification

Because decalcification carries both operational and quality risks, endpoint monitoring is repeatedly framed as essential. Common endpoint strategies include physical assessment (e.g., probing or bending) and chemical testing for residual calcium in solution, each serving to reduce the likelihood of both under-decalcification (leading to sectioning difficulty) and over-decalcification (leading to quality loss) (Dey, 2018; Newcomer

Supply, 2020). Standard operating procedures and technical guidance documents likewise emphasize that decalcification time is dependent on tissue size and density and that careful monitoring is required to prevent overexposure and preserve tissue suitability (Histopathology Section Standard Operating Procedures, 2020; Milestone, 2020).

From a laboratory quality standpoint, endpoint monitoring is a form of process control: it operationalizes consistency across samples and reduces preventable variation in tissue outcomes (Newcomer Supply, 2020; Histopathology Section Standard Operating Procedures, 2020). This is particularly relevant for comparative evaluations of decalcifying agents, because interpretive differences observed in morphology or IHC may be confounded if endpoints are not determined consistently across reagent conditions (Dey, 2018; Callis & Sterchi, 2013).

2.7 Synthesis and gap addressed by the present study

The literature cited in Manuscript A converges on several themes. First, decalcification is indispensable for mineralized tissue processing but can compromise morphology and biomolecular integrity if not carefully managed (Dey, 2018; Callis & Sterchi, 2013). Second, acid-based decalcification often improves speed but increases risk to nucleic acids and antigen preservation, with implications for both molecular diagnostics and immunohistochemistry (Wickham et al., 2000; Schrijver et al., 2016). Third, EDTA-based decalcification is consistently positioned as more preservation-oriented for morphology and downstream assays, though operationally slower and requiring monitoring discipline (Alers et al., 1999; Milestone, 2020).

These findings support the rationale for comparative assessment of decalcifying agents using measurable laboratory outcomes. Where laboratories must balance turnaround time with diagnostic quality, evidence-based selection becomes a methodological and quality assurance necessity rather than a matter of habit or convenience (Miquelestorena-Standley et al., 2020; Dey, 2018). The present study aligns with this literature-driven problem by comparing multiple decalcifying agents under standardized handling and evaluating outcomes through structured morphology and immunohistochemical quality indicators alongside decalcification performance metrics (Choi et al., 2015; Schrijver et al., 2016).

3. Materials and Methods

3.1 Study design and setting

The study employed a within-specimen comparative (paired) laboratory design to evaluate the performance of five decalcifying solutions on bone tissue quality and downstream staining outcomes. Each residual bone specimen served as its own control through subdivision and exposure to all study decalcifiers, thereby reducing between-specimen variability attributable to tissue source, baseline mineral density, and pre-analytic handling differences.

All laboratory procedures (fixation, decalcification, processing, embedding, microtomy, and staining) were conducted using the histopathology laboratory's standard operating procedures and routine quality controls, consistent with accepted practice in diagnostic histotechnology and pre-analytic specimen handling (Carson & Cappellano, 2016; Newcomer Supply, Inc., 2020; Thermo Scientific, 2020).

Residual bone specimens and specimen allocation

Residual bone slab specimens ($n = 10$) were obtained from diagnostic surgical pathology materials after routine clinical processing needs were satisfied. Each specimen was sectioned into five comparable slabs (target dimensions approximately $2.0 \text{ cm} \times 0.6 \text{ cm}$, with a thickness appropriate for timely decalcification and standard tissue processing), and each slab was assigned to one decalcifying solution. This paired allocation ensured that comparisons across decalcifiers were made within the same biologic source material rather than across different patients or tissue origins.

Fixation

All tissue slabs were fixed in 10% neutral buffered formalin (NBF) to preserve tissue architecture and cellular detail prior to decalcification. Fixation adequacy is a known determinant of morphology and immunoreactivity preservation, and insufficient fixation may compound decalcification-related protein degradation; thus, fixation was standardized prior to decalcifier exposure (Carson & Cappellano, 2016).

Decalcifying agents

Five decalcifying conditions were evaluated, representing commonly used strong-acid, weak-acid, chelating, and combination approaches in bone histopathology and in settings requiring downstream immunohistochemistry (IHC) and molecular testing (Castania et al., 2015; Choi et al., 2015; Lang, 2010; Skinner et al., 2013):

- a. 10% Hydrochloric acid (HCl) (strong acid)
- b. 15% Formic acid (weak acid)
- c. Gooding and Stewart solution (formalin–formic acid mixture; weak-acid based)
- d. EDTA-based decalcifier (commercially purchased MolDecal/MoL Decalcifier) (chelating agent)
- e. FEDTA (Formic acid + EDTA mixture) (combined weak acid + chelating condition)

Preparation of non-commercial solutions

All laboratory-prepared solutions were mixed using distilled water and appropriate chemical handling precautions.

- a. 10% HCl: 100 mL concentrated HCl added slowly to 900 mL distilled water.
- b. 15% Formic acid: 150 mL concentrated formic acid added slowly to 850 mL distilled water.
- c. Gooding and Stewart: 100 mL concentrated formic acid + 450 mL 10% NBF + 450 mL distilled water, mixed until homogeneous.
- d. EDTA-based solution: commercially purchased (MolDecal/MoL Decalcifier).
- e. FEDTA: 500 mL of 15% formic acid mixed with 500 mL EDTA-based decalcifier (1:1).

These selections reflect practical laboratory reality: strong acids shorten turnaround time but may compromise nuclear and protein integrity, whereas EDTA-based decalcification is widely recognized as gentler for antigen preservation and analytic reliability (Castania et al., 2015; Skinner et al., 2013).

Decalcification procedure and endpoint determination

Each slab was fully immersed in its assigned decalcifying solution using a solution volume sufficient to maintain effective ion exchange and consistent decalcification kinetics. The decalcification endpoint was determined using both physical and chemical testing, acknowledging that endpoint determination directly affects tissue quality and sectioning performance (Alers et al., 1999; Callis & Sterchi, 2013).

Physical endpoint test

Physical testing was conducted by assessing tissue resistance to gentle probing and flexibility at defined intervals, recognizing that excessive mechanical testing may introduce artifact; therefore, physical checks were performed conservatively and consistently across all groups.

Chemical endpoint test (calcium oxalate test)

Chemical testing was performed using the calcium oxalate precipitation principle: an aliquot of decalcifying fluid was collected, neutralized as required, and reacted with ammonium oxalate to detect residual calcium. The absence of precipitate was interpreted as completion of decalcification, consistent with classical endpoint testing in bone decalcification workflows (Alers et al., 1999; Callis & Sterchi, 2013).

Endpoint check schedule

Because strong acids decalcify rapidly and EDTA-based agents decalcify more slowly, the endpoint checks were scheduled according to expected kinetics to avoid both premature termination (undercalcification) and overexposure (overdecalcification). Strong-acid conditions were checked more frequently, while chelating and combination solutions were checked at longer intervals, consistent with the general decalcification behavior of these solution classes and the need to preserve histomorphology and antigenicity (Castania et al., 2015; Skinner et al., 2013).

Tissue processing, embedding, and microtomy

Upon reaching endpoint, tissue slabs were removed from decalcifying solutions and rinsed thoroughly to remove residual decalcifier, minimizing carryover that can interfere with processing and staining. Specimens were then processed using routine histopathology dehydration, clearing, and paraffin infiltration cycles, followed by embedding in paraffin blocks suitable for microtomy (Newcomer Supply, Inc., 2020; Thermo Scientific, 2020).

Paraffin blocks were sectioned into thin sections appropriate for routine H&E staining and IHC evaluation. Section thickness was standardized across groups to reduce staining variability attributable to cut depth and section thickness.

Hematoxylin and eosin staining and histomorphologic assessment

H&E staining was performed following standard histopathology protocols. Histomorphologic quality was assessed using a semi-quantitative scoring approach emphasizing structures commonly affected by decalcification-related artifact, including preservation of nuclear detail and extracellular matrix characteristics. The morphologic evaluation focused on features such as nuclear membrane integrity, chromatin pattern,

nucleolar clarity, cytoplasmic definition, and extracellular matrix preservation—features that directly influence diagnostic interpretability in bone histopathology (Carson & Cappellano, 2016; Skinner et al., 2013).

Immunohistochemistry and assessment of staining performance

IHC was performed using established automated staining protocols with appropriate positive and negative controls to evaluate antigen preservation across decalcification conditions. Four markers were examined—CD34, S100, SATB2, and SMA—representing diagnostically relevant targets in bone and soft tissue pathology contexts where decalcification may be required. This aligns with the broader rationale that pre-analytic decalcification conditions can materially affect IHC reliability and, by extension, analytic validity in modern diagnostic workflows (Lang, 2010; Skinner et al., 2013).

IHC outcomes were summarized using two complementary dimensions commonly used in semi-quantitative IHC reporting:

- a. Staining intensity (strength of signal), and
- b. Staining reactivity/extent (distribution or proportion of positive staining).

These dimensions were recorded systematically per specimen and per decalcifier condition to allow within-specimen comparisons across the five solutions.

3.2 Data management and statistical analysis

Because each specimen contributed measurements under all five decalcification conditions, the dataset is inherently paired (repeated-measures). Accordingly, statistical testing was specified to reflect within-specimen comparisons.

Descriptive statistics were computed for decalcification time and for morphology/IHC scoring outcomes.

For inferential analysis, outcomes were tested using a repeated-measures framework. If assumptions for parametric repeated-measures testing were not met (common for ordinal scoring outputs), a nonparametric repeated-measures approach was specified.

A two-sided significance threshold was set at $\alpha = 0.05$.

3.3 Ethical considerations

The specimens were residual diagnostic materials and were handled with confidentiality safeguards consistent with standard ethical practice for studies using archival or residual pathology materials. However, the publishable manuscript must explicitly state the ethics approval/waiver and the approving body (e.g., IRB/ethics committee name and approval code), because this is currently treated as a methodological completeness requirement in most journals.

4. Results and Discussion

4.1 Decalcification Endpoint

Table 1
Decalcification endpoint in hours*

Sample	10% HCl	15% Formic acid	Gooding & Stewart	EDTA	FEDTA
1	5	9	12	144	120
2	4	8	12	144	120
3	8	14	18	168	144
4	4	8	14	144	120
5	5	10	14	144	120
6	5	12	16	168	144
7	5	9	12	144	120
8	8	16	26	168	148
9	11	22	30	196	172
10	8	18	28	172	148
Ave.	6.30	12.60	18.20	159.20	135.60

* Decalcification endpoint is determined using physical and chemical tests.

The bone biopsies were decalcified accordingly, and the time was recorded.

Table 1 shows the decalcification endpoint of the ten samples using the five decalcifying agents. The 10% HCl had the fastest endpoint with an average time of 6.30 hours, followed by 15% formic acid, Gooding and Stewart, and FEDTA solution, while the EDTA solution had the slowest with an average time of 159.20 hours among the decalcified samples. The difference between the average time of 10% HCl and 15% formic acid was almost half, while the 15% formic acid over the Gooding and

Stewart revealed around 6 hours difference. The FEDTA significantly reduced the decalcification time to around 24 hours over the EDTA solution. This is more likely due to the formic acid solution added which caused the decalcification time faster. According to Miquelestorena-Standley et al. (2020) study, the optimal decalcification time was 2-2.5 times higher for formic acid, and 8-16 times higher for EDTA compared with a hydrochloric acid solution. Likewise, to other studies, EDTA decalcification requires longer days than other acid decalcifiers (Liu et al., 2017). However, HCl may be used as an alternative when rapid decalcification is needed (Choi et al., 2015).

4.2 Histomorphologic Structure in H&E Staining

Table 2 shows the mean histomorphologic structure preservation scores when stained with Hematoxylin and Eosin stain.

First, the 10% HCl preserved well the extracellular matrix. In contrast, the other bone cell structures such as the nuclear membrane, nucleoli, chromatin, and cytoplasm were moderately preserved, resulting in an equivalent good (G) remarks for the overall slide score of 10.75. Second, in the 15% formic acid solution, it yielded moderate mean scores in preserving all the histomorphologic structures with an overall good mean slide score of 10.40. Third is in the Gooding and Stewart or the formalin-formic acid solution. The cytoplasm and the extracellular membrane were well-preserved with mean scores of 2.85 and 2.75 respectively. On contrary, the nuclear membrane, nucleoli, and chromatin were moderately preserved with an overall excellent rating of 12.15. Fourth, the nuclear membrane, cytoplasm, and extracellular matrix in the EDTA solution were very well preserved with the following mean scores of 2.65, 2.90, and 2.95, respectively. However, the nucleoli and the chromatin were preserved moderately, with mean scores of 2.35 and 2.40. In the overall slide score, EDTA solution displayed excellent preservation for most of the population in the study with a mean score of 13.25 over 15. The result is likely due to the delicate nature of the EDTA towards the tissue's cellularity, resulting in excellent preservation of the

Table 2
Mean histomorphologic structure (HMS) preservation scores when stained with Hematoxylin and Eosin stain (H & E)

Decalcifying Agent	Nuclear membrane	Nucleoli	Chromatin	Cytoplasm	Extracellular matrix	Overall slide score
10% HCL	2.00 (M)	2.00 (M)	1.90 (M)	2.35 (M)	2.50 (E)	10.75 (G)
15% FA	1.95 (M)	1.65 (M)	1.90 (M)	2.45 (M)	2.45 (M)	10.40 (G)
G&S	2.35 (M)	2.00 (M)	2.20 (M)	2.85 (E)	2.75 (E)	12.15 (E)
EDTA	2.65 (E)	2.35 (M)	2.40 (M)	2.90 (E)	2.95 (E)	13.25 (E)
FEDTA	2.15 (M)	1.95 (M)	2.15 (M)	2.90 (E)	2.80 (E)	11.95 (E)

Legend: For mean histomorphologic scores: 0 - 0.49 - (P) poor - poorly preserved; 0.50 - 1.49 - (F) fair - fairly preserved; 1.50 - 2.49 - (M) moderate - moderately preserved; 2.50 - 3.0 - (E) Excellent - Well preserved. For assessing overall slide score, 0 to 3.49 - poor (P); 3.50 to 7.49 - fair (F); 7.50 to 11.49 - good (G) and 11.50 to 15.00 - excellent (E).

entire bone tissue's integrity. Likewise, in the rat's femoral bone research where the H&E staining showed good preservation of the tissue structures and cellular elements when decalcified using an EDTA solution (Castania et al., 2015). Alternatively, in the study of Liu et al. (2017) regarding morphology preservation, EDTA gives better results after 3% nitric acid, then followed by hydrochloric acid/formic acid solution. On the other hand, Choi et al. (2015) found no big differences with the morphological quality of H&E using the EDTA and the HCl-containing solution where both displayed well-preserved bone marrow histological features.

In formic acid-EDTA solution (FEDTA), nuclear membrane, nucleoli, and chromatin were moderately preserved. The cytoplasm and extracellular matrix were preserved excellently with an overall slide mean score of 11.95. Similar to the work of Castania et al. (2015) where EDTA is combined with HCl to enhance the speed of decalcification while maintaining the tissue's cellular contents and integrity.

4.3 Immunohistochemical Staining

Table 3 manifests the mean histomorphologic mean immunohistochemistry staining reaction scores.

In immunohistochemistry staining reaction using 10% HCl, CD34, S100, and SMA showed moderate signal with their subsequent mean scores of 2.20, 1.90, 1.70, and 2.30. The moderate result is unexpected due to the harsh effect of the HCl on living tissue. It is likely due to the careful monitoring of the decalcification endpoint. Contrary to the study of Bourhis et al. (2005) using anti-BRAFV600

marker fairly gave reactivity to the staining with a mean score of 1.70. Whereas CD34, S100, and SMA markers showed moderate reaction with mean scores of 1.90, 2.20, and 2.25, respectively. The fair SATB2 reactivity result suggests that 15% formic acid affects the bone osteocyte's immunohistochemical staining positivity. This is likely due to the high concentration and corrosiveness of formic acid on bone tissue. In contrary to Miquelestorena-Standley et al. (2020) study, short-term formic acid-based decalcification did not alter antigenicity and allowed molecular analysis of the bones.

In SMA immunohistochemistry marker using Gooding and Stewart solution showed an excellent signal with a mean score of 2.65. The other three antibodies displayed moderate reactivity with the following respective mean scores; CD34: 2.30, S100: 2.05, and SATB2: 2.10. The result is likely due to the balanced combination of a fixative and a decalcifying agent in one solution. Conversely, Naresh et al. (2006) study using 10% formic acid and 5% formaldehyde or Gooding and Stewart in their protocol for bone marrow specimens at Hammersmith Hospital, London. They found out that it exhibited an excellent morphology with good antigen, DNA, and RNA preservation.

The immunohistochemistry staining using EDTA solution for S100 and SATB-2 with mean scores of 2.14 and 2.21 both interpreted moderately showing reactivity in 25-50% of the cells. Furthermore, the CD34 and SMA marker showed excellent strong signal or reactivity in more than 50% of the cells with mean average scores of 2.50 and 2.75. The dominance of EDTA in the results of the four IHC markers is likely due to its neutral pH,

Table 3
Mean Immunohistochemistry (IHC) staining reaction scores

Decalcifying Agents	IHC Markers			
	CD34	S100	SATB2	SMA
10% HCL	2.20 (M)	1.90 (M)	1.70 (M)	2.30 (M)
15% FA	1.90 (M)	2.20 (M)	1.50 (F)	2.25 (M)
G&S	2.30 (M)	2.05 (M)	2.10 (M)	2.65 (E)
EDTA	2.50 (E)	2.25 (M)	2.45 (M)	2.75 (E)
FEDTA	2.55 (E)	1.70 (M)	2.10 (M)	2.65 (M)

Legend: For mean IHC effect scores: 0 - 0.49 - (P) poor – no signal; 0.50 - 1.49 - (F) fair – weak signal and/or reactivity in less than 25% of cells; 1.50 - 2.49 - (M) moderate - moderately signal and/or reactivity in 25-50% of cells; 2.50 - 3.0 - (E) Excellent – strong signal and reactivity in more than 50% of cells.

VE1 IHC yielded no positive results among four decalcified samples used with hydrochloric acid.

While the biopsies decalcified with 15% formic acid solution stained with IHC SATB2

delicate nature, and slow chelating decalcification effect on both bone and surrounding soft tissue. According to Choi et al. (2015), EDTA was the most feasible decalcifying agent for several types of

genetic studies and immunohistochemistry. Uniformly with Schrijver et al. (2016) study, concluded that EDTA-based decalcification is preferred for metastasized bone cancer biopsies because it allows fluorescence in situ hybridization and DNA/RNA isolation. As well as with the work of Miquelestorena-Standley et al. (2020), with EDTA decalcification, immunohistochemical proteins were well-preserved; however, it must be considered that EDTA is a slow decalcifying agent that might not be suitable for surgical specimens.

Lastly, the samples decalcified with FEDTA decalcifying solution and stained with S100, SATB-2, and SMA immunohistochemical markers revealed moderate signal while an excellent mean average score of 2.55 to CD34. The process may effectively reduce the decalcification endpoint. However, the results also demonstrate pH may affect the antigenicity of the bone tissue if EDTA is combined with acid decalcifiers. Nevertheless, the reactivity of the four IHC markers remains acceptable. Pontarollo et al. (2020) an equally significant study that concluded EDTA/formic acid decalcification could be used for immunohistochemical PD-L1 expression for lung cancer bone metastases. Another is the Castania et al. (2015) study, which found that EDTA with a combination of rapid decalcifiers such as HCl, which they called ETDA, showed similar tissue antigenicity preservation in comparison with the universally accepted EDTA solution. So, ETDA will be more advantageous than EDTA, for it will decrease the decalcification time significantly.

4.4 Comparison of H&E and IHC Staining Results

H&E Staining Results Comparison

In the nuclear membrane, it showed that there is a significant difference between HCl and EDTA ($p=0.019$), FA & EDTA ($p=0.023$), and EDTA and FEDTA ($p=0.029$); thus, the nuclear membrane preservation differs when compared to these decalcifying agents. Based on the result, the EDTA decalcifying agent exhibited the best nuclear membrane preservation. Furthermore, in the nucleoli, it was observed that there is a significant difference between FA and EDTA ($p=0.011$); hence, the nucleoli are well preserved when decalcified in EDTA solution. Another is in chromatin. It revealed a significant difference between HCl and EDTA ($p=0.015$) and FA and EDTA ($p=0.009$); consequently, EDTA solution dominated to be the best decalcifying agent in preserving chromatin. Also, in the cytoplasm, it was manifested that there is a significant difference between HCl and G&S ($p=0.019$), HCl and EDTA ($p=0.007$), HCl and FEDTA ($p=0.007$), FA and G&S ($p=0.029$), FA and EDTA ($p=0.011$), and FA and FEDTA ($p=0.011$); collectively, EDTA decalcifying agent displayed a well-preservation of the cytoplasm. In the extracellular matrix, there is a significant difference between HCl and EDTA ($p=0.015$) and FA and EDTA ($p=0.004$); subsequently, the EDTA solution presented the greatest extracellular matrix intactness and preservation. Lastly, in the overall slide score, it was proven that there is a significant difference between HCl and G&S ($p=0.035$), HCl and EDTA ($p=0.002$), FA and G&S ($p=0.005$), FA and EDTA ($p=0.000$), and FA and FEDTA ($p=0.009$); therefore, the EDTA solution was revealed to be the supreme decalcifying agent when compared to the other agents used. The superior results of EDTA in both H&E staining and IHC, with regards to preservation

Table 4
Multiple comparisons of the decalcifying agents stained with Hematoxylin and Eosin

Decalcifying Agents	Nuclear membrane		Nucleoli		Chromatin		Cytoplasm		Extracellular matrix		Overall slide score	
	p-value	I	p-value	I	p-value	I	p-value	I	p-value	I	p-value	I
1 HCL vs. FA	0.971	NS	0.123	NS	0.971	NS	0.579	NS	0.796	NS	0.684	NS
2 HCL vs. G&S	0.063	NS	1.000	NS	0.075	NS	0.019	S	0.190	NS	0.035	S
3 HCL vs. EDTA	0.019	S	0.165	NS	0.015	S	0.007	S	0.015	S	0.002	S
4 HCL vs. FEDTA	0.393	NS	0.912	NS	0.123	NS	0.007	S	0.123	NS	0.075	NS
5 FA vs. G&S	0.143	NS	0.143	NS	0.052	NS	0.029	S	0.105	NS	0.005	S
6 FA vs. EDTA	0.023	S	0.011	S	0.009	S	0.011	S	0.004	S	0.000	S
7 FA vs. FEDTA	0.481	NS	0.190	NS	0.105	NS	0.011	S	0.052	NS	0.009	S
8 G&S vs. EDTA	0.143	NS	0.218	NS	0.315	NS	0.971	NS	0.247	NS	0.123	NS
9 G&S vs. FEDTA	0.315	NS	0.971	NS	0.739	NS	0.971	NS	0.912	NS	0.739	NS
10 EDTA vs. FEDTA	0.029	S	0.165	NS	0.190	NS	1.00	NS	0.280	NS	0.075	NS

Legend: HCL: 10% Hydrochloric acid; FA: 15% Formic acid; G&S: Gooding and Stewart Solution; EDTA: 10% Ethylenediaminetetraacetic acid Solution; FEDTA: 5% Formic acid in 10% Ethylenediaminetetraacetic acid Solution; I: Interpretation; S: Significant; NS: Not Significant; p. value significant at less than 0.05 alpha level.

Table 4 displays the multiple comparisons of five decalcifying agents when stained with Hematoxylin and Eosin.

of bone tissue integrity and cellularity, are likely attributed to its pH neutrality and delicate effect on soft tissue. In morphologic preservation using H&E, a study by Liu et al. (2017) recommended a 3% nitric acid solution as the first choice followed by EDTA as the best decalcifying agent. Additionally,

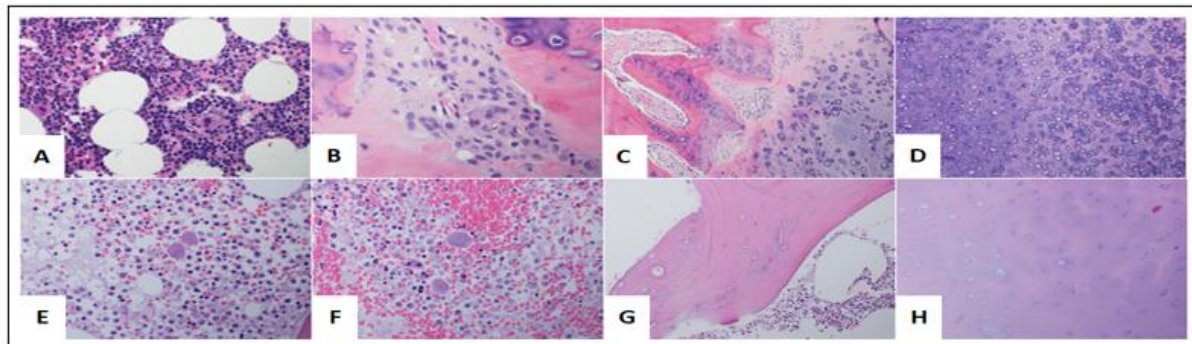


Figure 1. Representative histomorphologic structure (HMS) stained with H&E. (A-D) Excellent HMS staining decalcified in EDTA solution; (E-H) Poor HMS staining decalcified in 15% Formic acid solution. A&E: bone marrow; B&F: cellular features; C&G: extracellular matrix and bone; D&H: cartilage with chondrocytes.

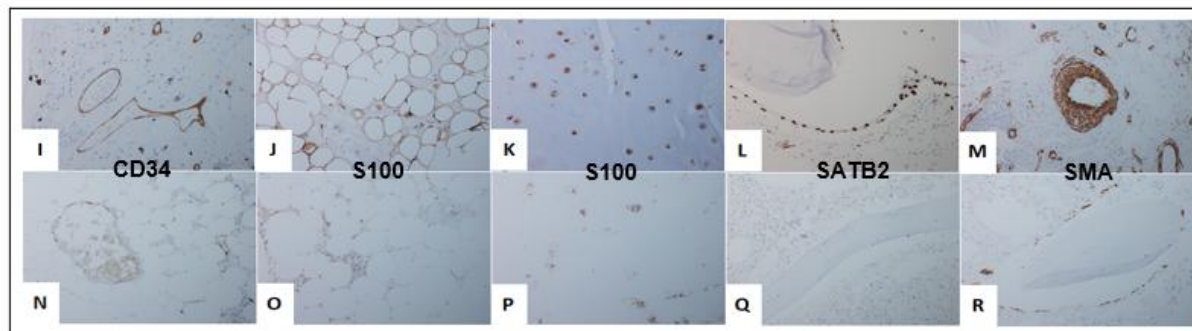


Figure 2. Representative immunohistochemical (IHC) staining. (I-M: EDTA) Strong IHC signal; (N-R: 15% FA) Weak IHC signal. I&N: vessel walls; J&O: adipocytes; K&P: chondrocytes; L&Q: osteocytes; M&R: smooth muscles and vessel walls

Castania et al. (2015) presented a study showing how EDTA and EDTA maintained good tissue preservation and integrity after decalcification. Similarly, Van Es et al. (2019) demonstrated that EDTA decalcification minimally impacts the expression of estrogen receptor (ER), progesterone receptor (PR), and human epidermal growth factor receptor-2 (HER2) in bone biopsies with metastatic breast cancer.

Additionally, several factors play a crucial role in proper bone tissue decalcification and must always be considered: adequate tissue fixation before the decalcification process, proper monitoring of the decalcification endpoint for each biopsy, and the correct concentration and volume of decalcifying solutions. Any mistake or mishandling can have an irreversible effect on tissue integrity.

4.5 IHC Staining Results Comparison

Table 5 exhibits the multiple comparisons of five decalcifying agents when stained with four immunohistochemical markers.

The results yielded no significant difference in the average scores among the five decalcifying agents using the four IHC markets, in contract with

many other related studies. This discordance may be due to the limited number of bone samples and IHC markers used in the study.

Table 5
Multiple comparisons on the effects of the decalcifying agents on immunohistochemistry (IHC) markers

IHC marker	Test statistic (χ^2)	p-value	Interpretation
CD34	5.538	0.236	Not Significant
S100	5.486	0.241	Not Significant
SATB2	6.504	0.165	Not Significant
SMA	8.909	0.063	Not Significant

Although no significant difference was found out among the agents, the 15% Formic acid showed the lowest mean score in CD34, SATB2, and SMA. At the same time, the EDTA dominated the top for S100, SATB2, and SMA while the EDTA for CD34, followed by the EDTA, which reflects strong signal and reactivity in more than 50% of the cells as shown in Figures 1 and 2.

Other related studies stated that EDTA decalcifying agent is the most feasible for genetic studies and Immunohistochemistry (Choi et al., 2015). Similarly, the research of Schrijver et al. (2016) using metastasized bone from the breast to evaluate immunohistochemistry expression using EDTA solution revealed excellent antigenicity preservation. Miquelstorena-Standley et al. (2020) likewise concluded that EDTA showed superiority in situ hybridization techniques, immunohistochemistry, gene mutation detection, and amplification. Furthermore, Van Es et al. (2019) study demonstrated that the EDTA decalcification of breast cancer bone metastases minimally affects the ER, PR, and HER2 results compared with acetic acid and hydrochloric/formic acid decalcifying agents. In addition, the study by Liu et al. (2017) published EDTA solution as one of the preferred decalcifying agents for immunohistochemistry studies using rat femurs. Moreover, Castania et al. (2015) used EDTA in their research as the universally accepted decalcifying agent in the preservation of cell structures and tissue antigenicity.

4.6 Discussion

This comparative evaluation highlights the practical reality that decalcification protocol selection is a workflow decision with direct diagnostic consequences—primarily a trade-off between turnaround time and preservation of interpretable histomorphology. In the present results, 10% HCl demonstrated the fastest mean endpoint time (6.30 hours), whereas EDTA required the longest mean endpoint time (159.20 hours); importantly, the FEDTA mixture reduced decalcification time to ~24 hours relative to EDTA, indicating that adding formic acid can accelerate endpoint achievement while retaining some performance features of EDTA-based processing.

The H&E outcomes indicate that EDTA produced the highest overall slide preservation (mean overall score 13.25/15, “excellent”), while Gooding & Stewart also yielded an “excellent” overall rating (mean 12.15/15). In contrast, the two acid-only conditions (10% HCl and 15% formic acid) showed “good” overall ratings (means 10.75 and 10.40, respectively), reflecting acceptable but comparatively lower preservation of key nuclear features.

These patterns are reinforced by the multiple-comparison results showing statistically detectable within-specimen differences across agents for several H&E metrics and for the overall slide score—supporting the inference that the choice of decalcifier meaningfully shifts routine morphologic interpretability, not merely speed.

For immunohistochemistry, the inferential results indicate no statistically significant

differences across decalcifiers for the four markers evaluated (CD34, S100, SATB2, SMA), with all tests reported as not significant.

Consistent with this, the narrative interpretation notes that despite non-significance, 15% formic acid tended to show the lowest mean scores for several markers, whereas EDTA tended to rank among the strongest for multiple markers, and FEDTA performed strongly for CD34.

In practical terms, these findings suggest that—under the study’s endpoint monitoring and laboratory conditions—IHC performance may be more robust than expected across the tested decalcifiers, or alternatively, that the study was underpowered to detect modest but clinically meaningful differences in IHC (especially when outcomes are semi-quantitative and marker-dependent).

From an applied laboratory perspective, the combined results support a defensible decision framework: EDTA is the strongest option when morphologic preservation is prioritized, but its prolonged endpoint time makes it operationally challenging for routine service demands; FEDTA offers a pragmatic compromise, materially improving turnaround time relative to EDTA while maintaining overall H&E quality in the “excellent” range.

When rapid reporting is essential, strong-acid protocols can be justified by speed, but the morphology results indicate that such choices should be matched to the clinical question, with heightened attention to endpoint monitoring and expected downstream testing needs.

Limitations and Future Research

Several limitations should temper interpretation. First, the study used a small number of specimens ($n = 10$) (Table 1), which limits statistical power—particularly for IHC where inter-marker variability is expected and effect sizes may be small.

Second, both H&E and IHC outcomes were captured through semi-quantitative scoring, which may introduce subjectivity unless inter-rater agreement, blinding, and calibration are explicitly documented.

Third, the IHC panel was limited to four markers; conclusions about “IHC preservation” should therefore be treated as panel-specific, not universal.

Fourth, results are laboratory-context dependent (e.g., fixation consistency, endpoint testing discipline, processing schedules), meaning

external generalizability should be established through replication rather than assumed.

Future research should (a) expand the sample size and include stratification by specimen density/thickness, (b) broaden the IHC marker panel to include more decalcification-sensitive targets, (c) explicitly quantify inter-rater reliability and/or use blinded slide review, and (d) incorporate downstream molecular endpoints (DNA/RNA integrity) to align protocol selection with contemporary integrated diagnostic workflows.

Additionally, controlled experimentation on FEDTA ratio, pH, agitation, and temperature would help identify an optimized “fast-but-protective” protocol that is operationally feasible without sacrificing interpretability.

5. Conclusion and Recommendations

5.1 Conclusions

Across the five decalcifying agents evaluated, the study demonstrated a clear trade-off between processing time and quality of histomorphologic preservation. In terms of decalcification endpoint, 10% HCl produced the fastest average endpoint (6.30 hours), whereas EDTA produced the slowest (159.20 hours), with FEDTA averaging 135.60 hours—representing an average reduction of approximately 24 hours relative to EDTA.

When outcomes were scored using H&E-based histomorphologic criteria, EDTA yielded the highest overall slide score (13.25; excellent preservation) compared with Gooding & Stewart (12.15; excellent) and FEDTA (11.95; excellent), while the strong and weak acids (10% HCl and 15% formic acid) obtained lower overall mean scores (10.75 and 10.40; both “good”).

These results support the conclusion that EDTA is the most effective agent for preserving histomorphologic structures in bone biopsy specimens intended for diagnostic histomorphology.

For immunohistochemistry, the scored outcomes across the four markers indicated no statistically significant differences among the five decalcifying agents, although mean patterns suggested EDTA remained a strong practical option (e.g., EDTA frequently ranked among the highest mean scores across markers).

Taken together, the findings indicate that while multiple agents can preserve IHC signal adequately under the conditions tested, EDTA most consistently supports histomorphologic integrity and remains a defensible first choice when diagnostic morphology is prioritized.

5.2 Recommendations

From a laboratory practice standpoint, the selection of decalcifying agent should be specimen- and purpose-specific, balancing morphology, IHC needs, and operational constraints. For small, tumoral, and delicate bone biopsies, a mild chelating approach (e.g., EDTA) is recommended to protect tissue structure for histomorphology and downstream staining, whereas for larger non-tumoral specimens (e.g., femoral heads, necrotic toes, amputations) where rapid processing is a priority, conventional acid decalcifiers may be more operationally appropriate.

In parallel, the study explicitly supports evaluating cost-effectiveness and turnaround time for EDTA across bone specimen types to guide a practical decalcification decision pathway.

For future research, it is recommended to (a) increase sample size and (b) expand the IHC marker panel to test whether subtle differences in antigen preservation emerge with broader diagnostic targets, particularly given that the absence of significant differences in this dataset may plausibly reflect the limited number of samples/markers.

Additionally, future work should extend evaluation to new IHC markers and expanding molecular assays to strengthen evidence for long-term tissue block utility after decalcification, especially in contemporary diagnostic workflows.

Acknowledgments:

The researcher is grateful to Mr. John Patrick Tadiosa of Lyceum of the Philippines University-Batangas, for the extraordinary support in completing this study. Additionally, to the following doctors, Dr. Khaled Murshed, Dr. Issam Al Bozom, and Dr. Adham Ammar; who read and graded the slides patiently. To the technical support of Ms. Zuhoor Al Sayyadi and Najah Al Fakieh at Hamad General Hospital, Histopathology Section, Doha Qatar. To Dr. Carina M. Magtibay, MSMLS program dean of LPU-Batangas, for her endless encouragement and motivation. Finally, to the Lord our God almighty and my family Michell, Gwenyth

Claire, and Gwenyvieve for their unending love and support.

6. References

- Alers, J. C., Krijtenburg, P. J., Vissers, K. J., & van Dekken, H. (1999). Effect of bone decalcification procedures on DNA in situ hybridization and comparative genomic hybridization: EDTA is highly preferable to a routinely used acid decalcifier. *Journal of Histochemistry & Cytochemistry*, 47(5), 703-709.
- Bourhis, A., Le Flahec, G., & Uguen, A. (2019). Decalcification can cause the failure of BRAF molecular analyses and anti - BRAFV600E VE1 immunohistochemistry. *Pathology International*, 69(4), 219-223.
- Bourhis, A., Flahec, G., & Uguen, A. (2019). Decalcification of bone specimens with sodium formate does not interfere with KRAS, NRAS, and BRAF mutation analysis in colorectal cancer. *BMC Gastroenterology*, 19(1), 207. <https://doi.org/10.1186/s12876-019-1115-4>
- Brown, R. (2009). Histologic preparations, common problems and their solutions (pp. 1–10). College of American Pathologists.
- Callis, G., & Sterchi, D. (2013). [Title not fully specified in Manuscript A reference list]. *Journal of Histotechnology*, 21(1), 49–58. <https://doi.org/10.1179/his.1998.21.1.49>
- Carson, F., & Cappellano, C. (2016). *Histotechnology: A self-instructional text* (4th ed.). ASCP Press.
- Chappard, D. (2015). Technical aspects: Bone histology. In *Bone cancer 2015* (pp. 5–14). Humana Press.
- Chappard, D. (2015). Technical aspects: How do we best prepare bone samples for histologic evaluation? In *Bone cancer and metastases* (2nd ed., pp. 111–120). Elsevier.
- Choi, S., Hong, S., & Yoon, S. (2015). Proposal of an appropriate decalcification method of bone marrow biopsy specimens in the era of expanding genetic molecular study. *Journal of Pathology and Translational Medicine*, 49, 236–242. <https://doi.org/10.4132/jptm.2015.03.16>
- Choi, S.-E., Hong, S. W., Shin, S.-J., Jeong, J., & Kim, D. (2015). Decalcification of bone metastases of breast cancer. *Clinical Pathology*, 202080, 1–6. <https://doi.org/10.5414/CP202080>
- Dey, P. (2018). Basic and advanced laboratory techniques in histopathology and cytology. Springer Singapore. <https://doi.org/10.1007/978-981-10-8252-8>
- Dey, P. (2018). Decalcification of bony and hard tissue for histopathology processing. In *Basic and advanced laboratory techniques in histopathology and cytology*. Springer Nature Singapore. https://doi.org/10.1007/978-981-10-8252-8_4
- Eloka, M. E., Sayed, S., & Brierly, J. (2012). The role of a mixture of EDTA and formic acid in decalcification. *Polish Journal of Radiology*, 77(2), 37–42. <https://doi.org/10.5114/pjr.2012.26773>
- Gao, Z., & Kahn, L. B. (2005). The application of immunohistochemistry in the diagnosis of bone tumors and tumor-like lesions. *Skeletal radiology*, 34(12), 755-770.
- Hamad Medical Corporation - Histopathology Section Standard Operating Procedures. (2020). [Institutional SOP]. Department of Laboratory Medicine and Pathology, Doha, Qatar.
- Hao, X., Kalscheur, V., & Muir, A. B. (2002). Decalcification of breast cancer bone metastases with EDTA does not affect ER, PR, and HER2 results. *Journal of Histotechnology*, 25(1), 33–37. <https://doi.org/10.1080/01478880209364643>
- Kapila, S. N., Natarajan, S., & Boaz, K. (2015). Novel method of decalcification for hard tissues. *Journal of Diabetes & Metabolic Disorders*, 29, 1–6. <https://doi.org/10.1016/j.jdiacomp.2014.11.008>
- Liu, J., Dong, H., Liang, Y., et al. (2017). Effects of different decalcification methods on the immunohistochemical detection of biomarkers in bone metastases of breast cancer. *Histochemistry and Cell Biology*, 148, 479–487. <https://doi.org/10.1007/s00276-017-1939-0>
- Milestone. (2020). MoL-Decalcifier: EDTA based decalcifying solution [Product page]. <https://www.milestonemedsrl.com/product/mol-decalcifier/>
- Miquelestorena-Standley, E., Jourdan, M.-L., Collin, C., Bouvier, C., Larousserie, F., Aubert, S., & Gomez-Brouchet, A. (2020). Effect of decalcification protocols on immunohistochemistry and molecular analyses of bone samples. *Modern Pathology*, 33, 1505–1517. <https://doi.org/10.1038/s41379-020-0503-6>



- Miquelestorena-Standley, E., Jourdan, M.-L., Collin, C., et al. (2020). Effect of decalcification protocols on molecular analysis and immunohistochemistry. *Clinical Pathology Review*, 12811, 1–9.
<https://doi.org/10.1111/cpr.12811>
- Newcomer Supply. (2020). Decalcification end point set—Technical sheet.
<https://www.newcomersupply.com/store/product/Decalcification%20End%20Point%20Set.1051.pdf>
- Schrijver, W. A. M. E., Van Der Groep, P., Hoefnagel, L. D. C., et al. (2016). Influence of decalcification procedures on immunohistochemistry and molecular diagnostics of bone metastases. *American Journal of Surgical Pathology*, 40(11), 1500–1508.
<https://doi.org/10.1097/PAI.0000000000000325>
- Schrijver, W. A., Van Der Groep, P., Hoefnagel, L. D., Ter Hoeve, N. D., Peeters, T., Moelans, C. B., & Van Diest, P. J. (2016). Influence of decalcification procedures on immunohistochemistry and molecular pathology in breast cancer. *Modern Pathology*, 29(12), 1460–1470.
- Thorat, R., Ingram, D. B., & Ferguson, A. (2011). Simultaneous fixation and decalcification. *Journal of Neuropathology & Experimental Neurology*, 70(8), 724–732.
<https://doi.org/10.1093/jnen/70.8.724>
- van Es, S. C., Bollen, E. C. M., van der Groep, P., et al. (2019). EDTA decalcification preserves ER, PR and HER2 results in breast cancer bone metastases. *Histopathology*, 75(4), 558–569.
<https://doi.org/10.1111/his.14011>
- Van Es, S. C., van der Vegt, B., Bensch, F., Gerritse, S., Van Helden, E. J., Boon, E., ... & Schröder, C. P. (2019). Decalcification of breast cancer bone metastases with EDTA does not affect ER, PR, and HER2 results. *The American Journal of Surgical Pathology*, 43(10), 1355–1360.
- Wickham, C. L., Boyce, R. W., & Prokopenko, O. A. (2000). The effects of decalcification on DNA in bone specimens: A comparison of EDTA and formic acid. *Journal of Histochemistry & Cytochemistry*, 48(8), 1123–1128.
<https://doi.org/10.1097/00000441-200008000-00014>
- Wickham, C. L., Sarsfield, P., Joyner, M. V., Jones, D. B., Ellard, S., & Wilkins, B. S. (2000). Formic acid decalcification of bone marrow trephines degrades DNA: Alternative use of EDTA allows the amplification and sequencing of relatively long PCR products. *Molecular Pathology*, 53(6), 336.
<https://doi.org/10.1136/mp.53.6.336>